

Aesthetic Plastic Surgery. 22:120-125, 1998

Browlifting with Thread: The Technique Without Undermining Using Minimum Incisions
Autores: Antonio Carmo Graziosi and Sandra Maria Canelas Beer

São Paulo, Brazil

Abstract

The position of the eyebrows exerts great influence over the upper eyelids, both in terms of skin excess as well as in the overall aesthetics of the lid/orbit region. Based on the need to associate the treatment of the eyelids with that of the eyebrows, the author developed an essentially simple surgical technique for browlifting. Through minimal incisions in the scalp and in the superior margin of the eyebrow, an anchor is made and traction is exerted with 00 cotton thread, without undermining in the frontal region, exception made by the thread line which is subgaleal. The main difference between this and other techniques is its use of the glide of the eyebrow over deep soft tissues, without the necessity of undermining. The followup ranged from 6 to 16 months, during which the lift remained at acceptable levels in most patients, while in a few cases it dropped down a little. This procedure was well accepted by the patients, making it a good alternative for the treatment of brow ptosis.

Key words: Browlift - Thread technique

Introduction

Brow ptosis, which is common in facial aging, can happen even in teenagers, principally in the lateral portion, causing the impression of a sad look.

A lowering of the eyebrow due to aging often results in excessive skin in the upper eyelid as well as a poorer overall aesthetic appearance in the orbital region.

Often due to the desires of the patient, the decision is usually made to correct the excessive skin by way of the relatively simple procedure of blepharoplasty, even though this severely limits the possibility for a future browlift. This is partially due to the patient's refusal to undergo a major operation, when the patient only wants blepharoplasty.

There are many techniques to perform browlifting, among them are those in which there is coronal access, with detaching surgical planes at several levels (subcutaneous, subglabellar, subperiosteal), which are based either on the traction and resection of the scalp with browlifting or on the correction of the position of frontal soft tissue over the bony area.

Using a small incision in the scalp, the endoscopic technique is based on the cutting of antagonistic muscles of the frontal muscle to elevate the brow with its contraction [10,11].

Another alternative is the incision in the frontal area with cutaneous resection in several places, such as the hairline, the medium frontal portion, and the areas above the eyebrows [1].

The browlifting through a pexy in the orbital periosteum is reported, with access through an incision of the superior blepharoplasty [6,12] or above the eyebrow [5].

Browlifting that keeps the eyebrows up in a higher position with surgical thread is also reported [2,7,8].

Our technique is included in this last group and its objective is to provide a simple procedure that can be used alone or as a complement to blepharoplasty and which avoids the disadvantages of a major surgery. Its main difference is the new concept using the eyebrow gliding over the deeper soft tissues without undermining. In this study, a comparison between our anatomic study and other recent ones (Knize) is made.

Case-Control Studies and Methods

The group studied was composed of 10 patients, ranging from 47 to 62 years old (average = 57.7 years old, eight females and two males. The follow-up period covered ranged from 6 to 16 months after surgery.

The browlifting was made with 00 nylon thread (three patients) and 00 cotton thread (seven patients). Three patients were treated with a lateral anchor, two patients with a medial anchor, and five patients with both kinds of anchor (Table 1).

Table 1. Browlifting

Paciente#	Age	Sex	Lift	Thread	Date	Follow-up (months)
1	54	F	Medial and lateral	Cotton 00	January 3, 1995	16
2	47	F	Medial and lateral	Nylon 00	April 24, 1995	15
3	54	F	Medial	Cotton 00	May 5, 1995	14
4	60	F	Medial	Nylon 00	May 15, 1995	15
5	61	F	Lateral	Cotton 00	July 20, 1995	12
6	42	F	Medial and lateral	Cotton 00	July 7, 1995	12
7	62	F	Medial and lateral	Nylon 00	June 26, 1995	13
8	54	M	Lateral	Cotton 00	August 14, 1995	11
9	54	F	Lateral	Cotton 00	January 31, 1996	6
10	49	M	Medial and lateral	Cotton 00	January 22, 1996	6

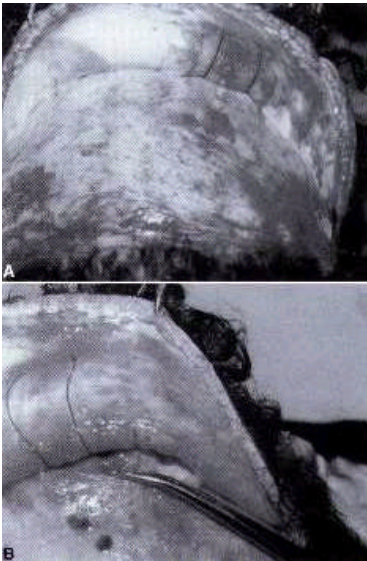


Fig1 Dissection of a cadaver, Observing the surgical planes and the thread trajectory.

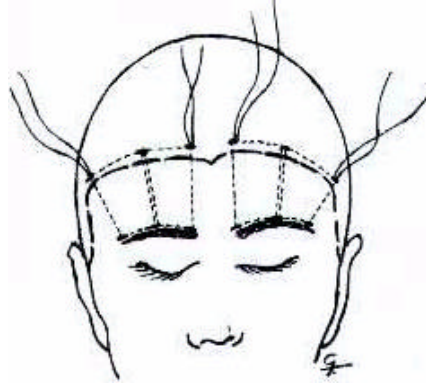

Fig2. Thread trajectory in medial lifting and in lateral lifting.

Surgical Planning

It was first necessary to diagnose the existing eyebrow alteration, observing its height in relation to superior orbit contour (in female patients, the eyebrow is located above this margin and in male patients, right on it), its conformation if there was lateral portion fall, medial portion fall or a fall of both portions, as well as asymmetries or skin excess in the frontal area. Based on this diagnosis for each patient, either lateral, medial, or both of the techniques of browlifting were programmed.

Surgical Technique

First, the patient is moved to a horizontal dorsal decubitus position with the patient's back elevated at 40° to facilitate the introduction of a thread guide and also for a better evaluation of the eyebrow. All procedures are made using local anesthesia.

According to the surgical planning, four or six incisions 2 mm in length are made with no. 11 blades in the frontal parietal area of the scalp 2 cm away from the hairline, keeping an equal distance between the eyebrows. These incisions go deep up to the periosteum. Using the special thread guide created by the authors, a safe passage of thread through surgical planes is made (Fig. 1).

The thread guide with a thread is introduced at the subgalia plane up to the superior eyebrow margin and then it goes outside through a 1-mm-long cutaneous incision over the eyebrow. The eyebrow anchor is made passing the thread across laterally using a 40 x 12 needle. The thread goes back to the scalp and then a traction and a knot are made, creating a rectangle (Fig. 2).

The traction intensity is regulated according to clinical evaluation before surgery and also by the surgeon's feel (generally with hypercorrection).

The incisions are sutured with 1 stitch using 6.0 nylon thread and a dressing is compressed, remaining for 24 h.

Evaluation

To evaluate the results, photographs were taken before and after surgery by the same photographer from three different positions, but using the same camera, flash, and distance.

Each patient had a protocol with identification, general evaluation, and specific evaluation of the orbital area. The distances from the internal corner ligament up to the inferior eyebrow margin and from the external corner ligament to inferior margin of the eyebrow point were measured. All surgeries were made by the same surgeon, and surgery descriptions were written down including information about the locale and the thread used.

A questionnaire with 10 questions was filled out for each of the patients. Five of these questions were answered by each of five doctors (the surgeon himself and four others, Table 2). The questions from the individual evaluation were graded, the results being classified as bad, regular, or good according to the table presented below.

Results

Some clinical results are shown by the photos in **Figs. 3** and **4**, while the results of the patient and doctor evaluations are shown in **Tables 3** and **4**, below.

Table 2. Questionnaire

	Pacient	Surgeon*	Doc B	Doc C	Doc D	Doc E
Eyebrows improvement						
Reduction of skin excess from the superior eyelid						
Naturalness othe eyebrow form						
Quality of the scars						
Final result						
Visual temporal field improvement						
Itraoperative evaluation (pain, discomfort)						
Postoperative evaluation						
Recomendability of procedure for other patients						
Opinion of friends/relatives						

Evaluation of results Classification: Bad: 0-4; Regular: 4.1-7; Good: 7.1-10.

OBS: Question nos. 1 to 5 - evaluated by patient and dostors; question nos. 6 to 10 - evaluated by patient

* Author 1.

Table 3. Evaluation made by patients and doctors

Good	Regular	Bad	
Eyebrow position improvement	4	3	3
Reduction of Skin excess	4	3	3
Naturalness of the superior eyelid	10	0	0
Quality of the scar	10	0	0
Final results	4	6	0

Table 4. Evaluation made only by patients

	Good	Regular	Bad
Visual temporal field Improvement*	8	-	-
Intraoperative evaluation (pain, discomfort)	5	5	0
Postoperative evaluation**	3	2	5
Recommendability of the surgery for other patients	10	-	-
Opinion of friends/relatives	9	1	0

* Two patients did not have previous difficulties

** Patients had after the surgery for variable period, around 3 weeks after surgery.

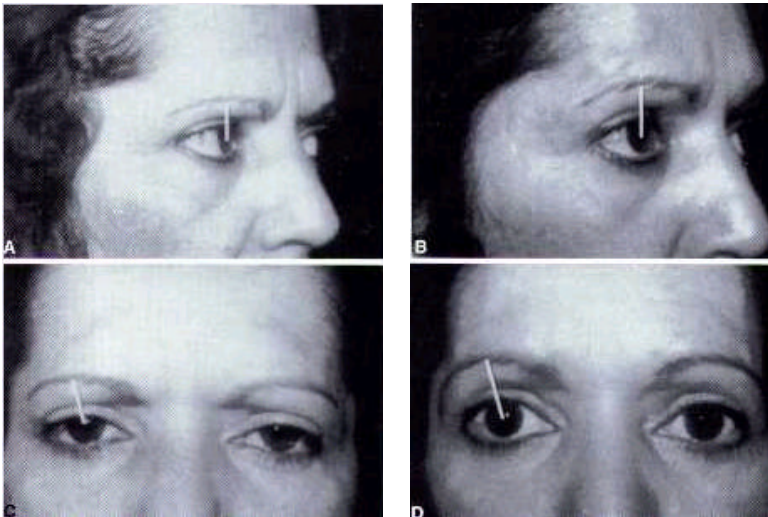

Fig 3. Patient EGO (Protocol no.2). (A,C) Preoperative; (B,D) 16 months postoperative.

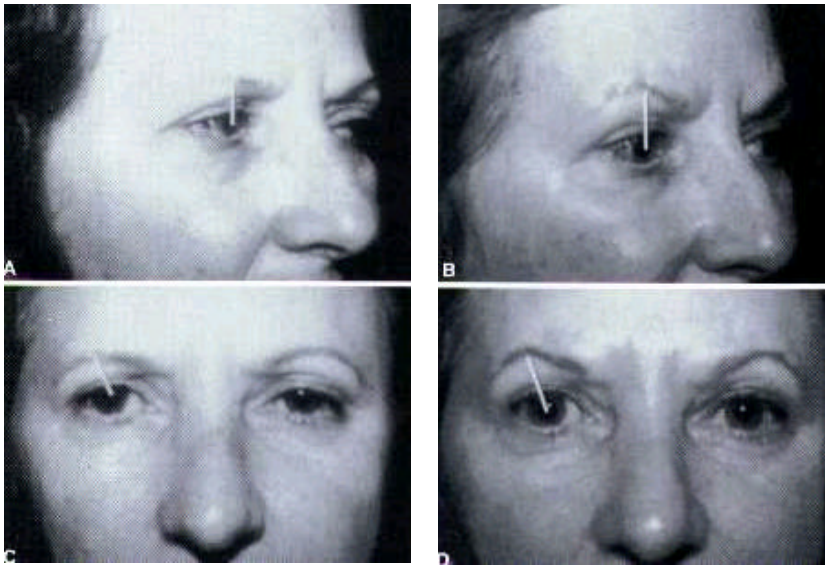


Fig 4. Patient EGO (Protocol no.2). (A,C) Preoperative; (B,D) 6 months postoperative.

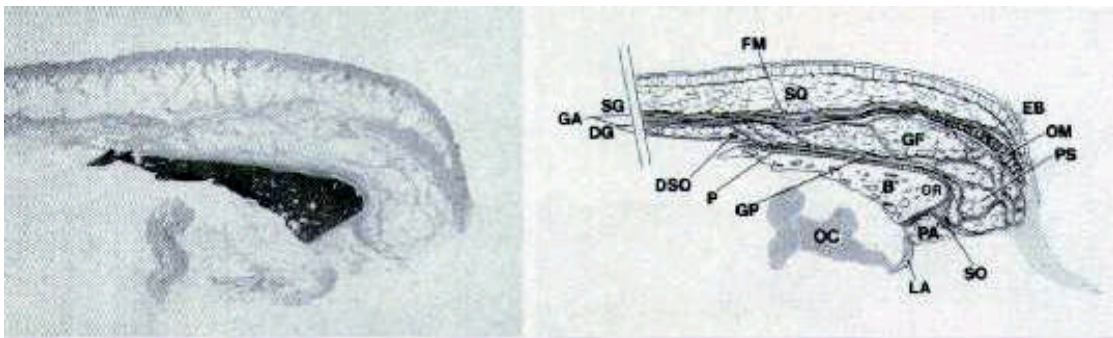


Fig. 5. On the left, histological cut in the eyebrow area stained by Masson's trichrome method. On the right, the figure shows the fat area over which the eyebrow is located. The following abbreviations stand for the descriptions below: eyebrow (SC), frontal muscle (MF), orbicular muscle (MO), aponeurotic galea(GA), fat area of the galea (GG), preseptal fat (GPS), orbital margin (OCRB), orbit cavity (CO) (KNIZE, D.M. An anatomically based study of the mechanism of eyebrow ptosis. (Source: From Ref. 3.)

Discussion

This technique is based on the experience of the authors in frontalis suspension in correction of ptosis of eyelids, adapted for eyebrow ptosis.

Many studies concerning eyebrow ptosis have already been published, presenting different techniques and lifting experience, and there have also been several anatomic studies for a better understanding of eyebrow ptosis. This indicates the great interest and importance of the theme and also demonstrates the great diversity of treatment methods. Among these methods, the coronal incision has been most frequently used. Psillakis [9] noticed good results in a 5-year follow-up of surgeries using this incision in the subperiosteal plane [9]. However, as it is major surgery, many patients do not want it as a complement to blepharoplasty.

The advantages of the coronal incision are the possibility of direct incision in the frontal muscles permitting the treatment of local wrinkles, a more accurate homeostasis, the treatment of bony parts, cutaneous resection, and hidden scars. Its disadvantages are complications such as the loss of scalp sensitivity, alopecia in the incision lines, long although covered, surgical scars, skin necrosis, great skin detachments in the frontal and temporal areas, as well as limitation in cases of bald patients and patients with a high forehead.

The cutaneous incisions in the frontal area are more appropriate for older patients. The great disadvantage of the technique is the existence of scars, which at times are bad. Often, there can be also ptosis recidivism.

Browlifting with thread, which is supported by anatomic studies (Fig. 5), would be in the pexy group. The main difference between this technique and others (3,4) is the concept of using the glide of the eyebrow over the soft tissues, without the necessity of undermining.

The traction is made vertically (which would be the maximum elevation vector), and the tractioned skin is distributed over the frontal area between the eyebrow and the scalp.

Basically, this technique presents the following advantages:

1. Minimum scars.
2. There is no undermining (except in the thread path).
3. It is a simple surgery made with local anesthesia at an outpatient department.
4. Intact mimic.
5. The lifting can be made sectorially and the traction can be adjusted in cases of asymmetry.
6. Low cost because it is made using nonsophisticated material at an outpatient clinic.
7. Good acceptance by patients due to its being a minor surgery, causing unobtrusive scars, and keeping the possibility of returning to the original situation by just removing the thread. Surgery can be programmed and made independently of a superior blepharoplasty, that is to say, individuals who only need an eyebrow treatment.

The disadvantages are as follow:

1. Ptosis recidivism in varying levels, as in other techniques.
2. The greater the age, the more the cutaneous excess in the frontal region there is and the more difficult the accommodation is, in spite of the patient's approval.
3. The frontal wrinkles cannot be treated.
4. Need of eyebrow incision, although minimal and imperceptible.
5. Anatomic alteration of the eyebrow in the initial postoperative.

According to the results obtained through the questionnaire, a great number of patients were satisfied. Among all evaluations, the most critical was that of the surgeon. It is also important to mention that in four patients the results were good, and as two of these were followed up for more than 1 year, the durability of the results obtained was confirmed. Another important observation is the functional aspect, because those patients who had troubled vision showed improvement of the visual temporal field. The eyebrow position measurement might not be accurate, mainly because of the impossibility of determining the exact limits of the eyebrow.

It is believed that with better screening of potential patients and the use of nonabsorbable thread-which can be more involved by fibrotic processes-the number of good results will be increased.

References

1. Castanares MSS: Forehead wrinkles, glabellar frown and ptosis of the eyebrows. *Plast Reconstr Surg* 34(4):406, 1964
2. Horibe EK, Horibe K, Lodovici O. Lifting of the eyebrows in blepharoplasties. *Aesth Plast Surg* 13:179-182, 1989
3. Knize DM: An anatomically based study of the mechanism of eyebrow ptosis. *Plast Reconstr Surg* 97(7):1323-1333, 1996
4. Lemke BN, Stasior OG: The anatomy of eyebrow ptosis. *Area Ophthalmol* 100:981-986, 1982
5. Lewis JR, Jr.: A method of direct eyebrow lift. *Annals Plast Surg* 10(2):115-119, 1983
6. McCord CD, Doxanas MT: Browplasty and browpexy: An adjunct to blepharoplasty. *Plast Reconstr Surg* 86(2):248-254, 1990
7. Morselli PG. Fixation for forehead endoscopic lifting: A simple, easy, no-cost procedure. *Plast Reconstr Surg* 97(6):1309-1310, 1996
8. Paul MD: Subperiosteal transblepharoplasty forehead lift. *Aesth Plast Surg* 20:129-134, 1996
9. Psillakis JM: Subperiosteal approach for surgical rejuvenation of the upper face. In Psillakis JM (ed): *Deep face lifting techniques*. New York: Thieme Medical Publishers, Inc., 1994
10. Ramirez OM: Endoscopic techniques in facial rejuvenation: An overview, Part I. *Aesth Plast Surg* 18:141-147, 1994
11. Ramirez OM: Endoscopically assisted biplanar forehead lift. *Plast Reconstr Surg* 96(2):323-333, 1995
12. Sokol AB, Sokol TP: Transblepharoplasty brow suspension. *Plast Reconstr Surg* 69(6):940-944, 1982

Web textos and figs.: GUTO GOMEZ